

# Morpho-histochemical study of the biological effects of sodium dodecyl sulphate on the digestive gland of the Portuguese oyster

M. Rosety, A. Ribelles, M. Rosety-Rodriguez, C. Carrasco, F.J. Ordoñez and J.M. Rosety

Department of Morphological Sciences, School of Medicine, University of Cadiz, Cadiz, Spain

**Summary.** In the present work we have studied the effects on survival as well as histopathological and histochemical alterations on the digestive gland of the Portuguese oyster (*Crassostrea angulata*, Lmk.) induced by acute action of the anionic tensioactive Sodium Dodecyl Sulphate (SDS) at different concentrations (50, 100, 200 and 400 mg/L).

Firstly, the LC 50 at 96 h was found to be 136 mg/L SDS. Secondly we calculated the exposure time required for 50% mortality of the specimens exposed to different concentrations, and thirdly we examined histopathological alterations (degenerative processes ranging from inflammatory responses to extreme vacuolation) and histochemical changes in the distribution of carbohydrates and proteins that appeared at each employed concentration.

The degree of these alterations and the effects on survival were dependent upon the SDS concentration. The above established modifications indicate that exposure to SDS has a detrimental effect on oyster digestive gland, perturbing metabolic and nutritional functions, what may have some influence on oyster survival.

**Key words:** Contamination, Sodium Dodecyl Sulphate, Bivalve, *Crassostrea angulata*, Digestive gland, Histopathology

## Introduction

In a developed, industrialized society, the use of detergents is an important fact, since they are used in an important number of daily activities in our life (Mayolle, 1962).

Surfactants are active components of detergent compounds. Anionic ones are 70% of total production, and among them, Sodium Dodecyl Sulphate (SDS) is the

most widely commercialized (Garcia Dominguez, 1986).

The main problem that this substance produces is its elimination with urban and industrial residual waters towards rivers and seas where they produce a variety of toxic effects on aquatic animals (Fendinger et al., 1994). In this respect, although they are biodegradable substances (Bogan, 1955; Flores et al., 1979) their biological effects may persist on the aquatic life while degradation of intermediate products is not complete (Abel, 1974; Marchetti, 1985).

This experiment was conducted to ascertain the effects of anionic tensioactive SDS, at different concentrations (50, 100, 200 and 400 mg/L), on portuguese oyster *Crassostrea angulata* Lmk.

*Crassostrea angulata*, Lmk. is a bivalve mollusc which is found along the Mediterranean and South Atlantic coasts of Europe. Aquaculture for oysters increased during the 1970's and 1980's although due to changes in the market, the industry dried up. There has recently been a rebirth in interest in the aquaculture industries all over the Atlantic provinces (Dennis, 1998).

As a filtrating mollusc it is able to absorb and accumulate in its organism the substances dissolved in the water (Gardiner, 1992). Consequently, bivalves have been extensively used as bioindicators of pollution in aquatic environments, particularly in coastal areas worldwide. The use of molluscs as biomonitors of heavy metal pollution (Lopez-Artiguez et al., 1989; Sarasquete et al., 1997) has been well established. It has also been studied the impact that polynuclear aromatic hydrocarbons (Norena-Barroso et al., 1999) tributyltin (Alzieu, 1998) and residues of organochlorine insecticides (Yoon et al., 1996) produced in oysters. However the information regarding the effects of surfactants on bivalves is very limited (Benjumea et al., 1996; Blasco et al., 1999).

The digestive gland or hepatopancreas is a symmetric and odd organ which surrounds the stomach. This organ develops the functions of digesting, absorbing and accumulating reserve substances. It produces carbohydrases, proteases and lipases which are involved in the intracellular digestion (Castello, 1993).

The specific objectives of this work were to

determine the LC 50 at 96 h as well as the exposure time required for 50% mortality of the specimens at different concentrations (50, 100, 200, 400 mg/L SDS) in order to evaluate the effects of surfactants on oyster survival. Finally, to examine histopathological alterations as well as the histochemical distribution of carbohydrates (neutral mucopolysaccharides, glycogen and acid mucopolysaccharides) and proteins (proteins in general, siderophile proteins, proteins rich in SH groups –cysteine- and proteins rich in SS groups –cystine-) in the digestive gland of portuguese oyster (*Crassostrea angulata*, Lmk) that appeared at each concentration.

### Materials and methods

Adult healthy oysters, *Crassostrea angulata*, Lmk., used in this investigation were 10 cm long and weighed 80 g with the valves, on average. They all proceeded from a marine farm.

A total amount of 50 viable specimens were used, 10 of them as a control lot. The rest were divided into 4 lots (A, B, C and D), which were exposed to SDS concentrations of 50, 100, 200 and 400 mg/L respectively. Control oysters were maintained under identical conditions without the addition of the surfactant.

Each group, containing ten specimens, was maintained in a PVC tank containing 15 litres of sea water whose characteristics were as follows: salinity 30‰, pH 7.4, temperature 16-18 °C, dissolved oxygen 8-8.6 mg/L, total hardness 100 mg CO<sub>3</sub>Ca/L, surface tension 72.7 Nm/m, absence of heavy metals and contamination due to aerobe and anaerobe micro-organisms.

To prevent the surfactant loss, a closed circuit was used. To avoid great variations in tensioactive concentrations, test solutions were changed every 12 hours. The biodegradation occurring in this time was

less than 10% of the initial concentration (Flores et al., 1980).

The most obvious feature of a bivalve is the protective shell. Oysters shut their valves so they isolate their body tissues from changes in the external environment. Two holes of 5 mm diameter and 1 cm apart, were made in a valve of each animal to prevent the oyster isolation as a reaction against toxic substances.

Since the death of the oysters is often not-directly observable, oysters failing to close their shell as a response to external stimuli, when removed from water, were considered dead. The LC 50 causing death in a period of 96 hours was determined according to Sprague (1976) and Loomis (1982).

Once we have noted the exposure time required for 50% mortality of the specimens at each concentration, we selected viable specimens from the same lot to examine histopathological and histochemical changes that appeared at each tested concentration.

After that, their digestive gland was quickly removed and fixed in 10% (v/v) formol buffered with phosphate buffer 0.1 M, pH 7.2 (Martoja and Martoja-Pierson, 1970), dehydrated in increasing concentrations of alcohol, cleared with benzol and embedded in semisynthetic paraffin wax with a mean fusion point of 54-56 °C. Sections were cut at 5 µm.

Harris's Hematoxylin and Acetic Eosin and Harris's Hematoxylin-V.O.F. (Gutiérrez, 1967) were employed as general stains. Histochemical reactions on carbohydrates and proteins in the digestive gland were employed to assay pollution effects. In this respect, it may be noted that histochemical results (Tables 1, 2 and 3) were expressed as semiquantitative assessment of colour intensities by independent scores of three investigators.

### Results

The LC 50, extrapolating the results on

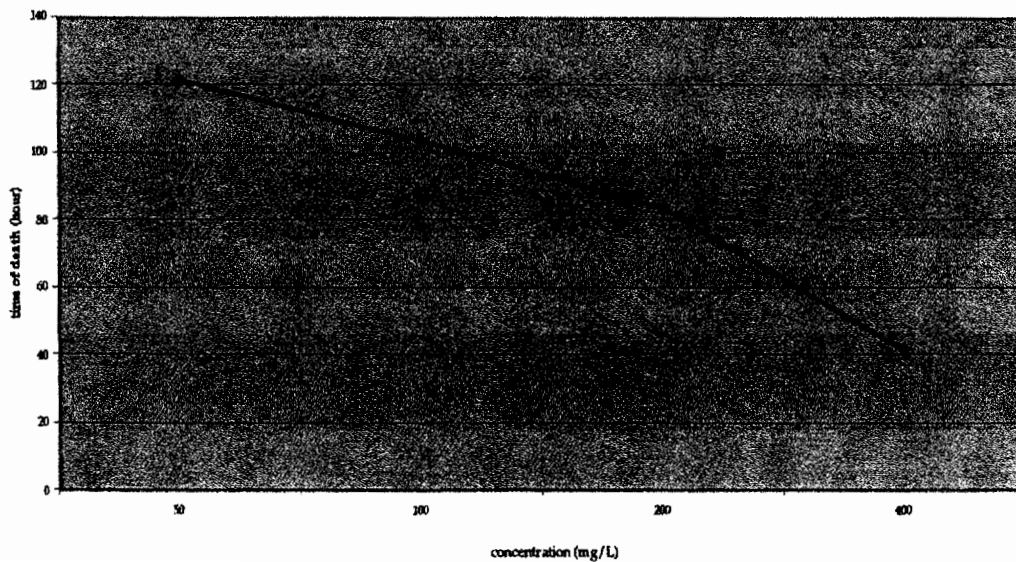


Fig. 1. Time of death of 50% of *Cassotrea angulata*, Lmk, at each concentration.

*Effects of SDS on the digestive gland of the Portuguese oyster*

semilogarithmic paper, at 96 hours for *Crassostrea angulata*, Lmk. was found to be 136 mg/L of SDS. Exposure times required for 50% mortality of the specimens resulting at each concentration are presented in Figure 1. At 50, 100, 200 and 400 mg/L SDS, oysters took 122, 104, 84 and 42 hours respectively to reach 50% mortality. No mortality occurred in control lot.

### Controls

The sections obtained from untreated specimens revealed the normal histological and histochemical patterns of the digestive gland which is formed by digestive diverticula and ducts. Digestive diverticula and ducts are surrounded by a connective tissue and some isolated muscle fibers that gave a lobulated look to the gland (Gardiner, 1992). In this respect, the digestive diverticula are made of a large number of blind tubules emptying into several large ducts which lead to the interior of the stomach.

In cross section tubules are usually round with a lumen in the form of a cross. The digestive cells which form the interior of a tubule consisting of columnar acidophilic or secretory cells and pyramidal basophilic or generative cells.

The histochemical behaviour of both digestive cells was as follows:

#### Secretory cells

PAS reaction was moderate and although it did not

decline after enzymatic digestion with Diastasa PAS, it decreased to weak after Alpha-Amilase PAS treatment. Alcian Blue at pH 0.4 showed a weak presence of sulphated mucopolysaccharides strongly ionized. Bromophenol Blue technique was negative and Hartig Zacharias method was moderately positive, suggesting the moderate presence of siderophile proteins. Potassium Ferricyanide- Fe (III) was weakly positive, indicating the presence of proteins rich in SH groups (cysteine) and other reductor groups. Thioglicolate-Potassium Ferricyanide-Fe (III) was also weakly positive, indicating the presence of proteins rich in S-S groups (cystine).

#### Regenerative cells

They showed a moderate reactivity to PAS which did not decline after enzymatic digestion. Bromophenol Blue and Hartig Zacharias method were both moderately positive. Potassium Ferricyanide-Fe (III) was moderately positive and Thioglicolate-Potassium Ferricyanide-Fe (III) was strongly positive.

The ducts, that connect the tubules with the stomach, are circular in cross section and are lined with columnar ciliated epithelium. Their lumen is, however, irregular due to the variations in the height of the epithelial cells. The histochemical results were: PAS reaction was moderately positive and although it decreased to weakly positive after enzymatic digestion with Alpha-Amilase PAS, it was not modified after Diastase PAS treatment. Alcian Blue at pH 0.4 was weakly positive.

**Table 1.** Histochemical reactions on carbohydrates and proteins in Acidophilic or Secretory cells of the digestive gland of *Crassostrea angulata* Lmk. exposed to different concentrations of Sodium Dodecyl Sulphate (SDS).

REACTIONS	CT	A	B	C	D
PAS (McManus, 1948) Adjacent hydroxyl groups	2	2	2	2	NP
DIASTASE-PAS (Lillie and Greco, 1947) Glycogen	2	2	2	2	NP
ALPHA-AMILASE-PAS (Lillie and Greco, 1947) Neutral mucosubstances and/or glycoproteins, excepting glycogen	1	1	1	1	NP
ALCIAN – BLUE pH 2.5 (Martoja and Martoja-Pierson, 1970) Carboxyl-rich glycoconjugates, sulphated or not	0	0	0	0	NP
ALCIAN – BLUE pH 1 (Martoja and Martoja-Pierson, 1970)	0	0	0	0	NP
ALCIAN – BLUE pH 0.4 (Martoja and Martoja-Pierson, 1970) Sulphated glycoproteins, strongly ionized	1	0	0	0	NP
BROMOPHENOL BLUE-Hg (Chapman, 1971) Proteins in general	0	0	0	0	NP
HARTIG ZACHARIAS (Martoja and Martoja-Pierson, 1970) Siderophile proteins	2	1	1	1	NP
POTASSIUM FERRICYANIDE-Fe (III) (Chevremont and Frederic, 1943) Proteins rich in SH groups	1	0	0	0	NP
THIOGLICOLATE POTASSIUM FERRICYANIDE-Fe (III) (Chevremont and Frederic, 1943) Proteins rich in S-S groups	1	1	1	1	NP

CT: control group; A: 50 mg/L SDS; B: 100 mg/L SDS; C: 200 mg/L SDS; D: 400 mg/L SDS. Results are expressed as semiquantitative assessment of color intensities by independent scores of three investigators. Estimated scale: 0, negative; 1, weak; 2, moderate; 3, strong; NP, has not been performed.

Bromophenol Blue was negative while Hartig Zacharias method was moderately positive indicating the presence of siderophile proteins. Potassium Ferricyanide-Fe (III) and Thioglycolate-Potassium Ferricyanide- Fe (III) were both weakly positive.

#### Lot A (50 mg/L SDS)

The most striking feature was the loss of cilia in some areas of the columnar ciliated epithelium that lined the ducts. Most of the digestive cells appeared to be in good condition with no obvious abnormalities.

Histochemical changes observed at this concentration were:

##### Secretory cells

The results of histochemical reactions on carbohydrates were similar to control lot, except Alcian Blue at pH 0.4 stain that decreased to negative. Siderophile proteins decreased slightly respect to controls, Potassium Ferricyanide-Fe (III) decreased to negative and Thioglycolate-Potassium Ferricyanide-Fe (III) was not modified respect to control.

##### Regenerative cells

Histochemical results on carbohydrates did not vary. Proteins in general decreased to weak although siderophile proteins were equal than control. Potassium Ferricyanide-Fe (III) was negative and Thioglycolate-

Potassium Ferricyanide-Fe (III) decreased to moderate.

##### Epithelial ciliated cells

PAS reactivity decreased slightly respect to control. It decreased to negative after alpha-Amilase PAS treatment but it was not modified after Diastase PAS digestion. Staining with Alcian Blue at pH 0.4 decreased to negative. The results Bromophenol Blue and Hartig Zacharias method were similar to controls. Potassium Ferricyanide-Fe (III) was negative and Thioglycolate-Potassium Ferricyanide-Fe (III) maintained a weak presence.

#### Lot B (100 mg/L SDS)

There was a more intense loss of cilia and erosion of the cytoplasm of the ciliated columnar cells. As compared with controls, digestive cells showed a moderate vacuolation of the cytoplasm

Histochemical changes were as follows:

##### Secretory cells

Histochemical results were not modified respect to lot A.

##### Regenerative cells

The results on carbohydrates were similar to those

**Table 2.** Histochemical reactions on carbohydrates and proteins in Basophilic or Regenerative cells of the digestive gland of *Crassostrea angulata* Lmk. exposed to different concentrations of Sodium Dodecyl Sulphate (SDS).

REACTIONS	CT	A	B	C	D
PAS (McManus, 1948) Adjacent hydroxyl groups	2	2	2	2	NP
DIASTASE-PAS (Lillie and Greco, 1947) Glycogen	2	2	2	2	NP
ALPHA-AMILASE-PAS (Lillie and Greco, 1947) Neutral mucosubstances and/or glycoproteins, excepting glycogen	2	2	2	2	NP
ALCIAN - BLUE pH 2.5 (Martoja and Martoja-Pierson, 1970) Carboxyl-rich glycoconjugates, sulphated or not	0	0	0	0	NP
ALCIAN - BLUE pH 1 (Martoja and Martoja-Pierson, 1970)	0	0	0	0	NP
ALCIAN - BLUE pH 0.4 (Martoja and Martoja-Pierson, 1970) Sulphated glycoproteins, strongly ionized	0	0	0	0	NP
BROMOPHENOL BLUE-Hg (Chapman, 1971) Proteins in general	2	1	0	0	NP
HARTIG ZACHARIAS (Martoja and Martoja-Pierson, 1970) Siderophile proteins	2	2	2	2	NP
POTASSIUM FERRICYANIDE-Fe (III) (Chevremont and Frederic, 1943) Proteins rich in SH groups	2	0	0	0	NP
THIOGLICOLATE POTASSIUM FERRICYANIDE-Fe (III) (Chevremont and Frederic, 1943) Proteins rich in S-S groups	3	2	2	2	NP

CT: control group; A: 50 mg/L SDS; B: 100 mg/L SDS; C: 200 mg/L SDS; D: 400 mg/L SDS. Results are expressed as semiquantitative assessment of color intensities by independent scores of three investigators. Estimated scale: 0, negative; 1, weak; 2, moderate; 3, strong; NP, has not been performed.

*Effects of SDS on the digestive gland of the Portuguese oyster*

appeared at controls. Proteins in general were negative while siderophile proteins were moderate.

Epithelial ciliated cells

Histochemical changes were similar to those observed in lot A.

*Lot C (200 mg/L SDS)*

Surfactant treatment produced an extreme vacuolation of digestive cells, a strengthening of the basement membrane and the appearance of basal membrane bound vesicles. We also appreciated tubule dilation and tubule breakdown in some areas.

Secretory cells

Histochemical results did not vary respect to lot A.

Regenerative cells

Histochemical results were similar to those obtained in lot B

Epithelial ciliated cells

Histochemical behaviour was similar to lot A except siderophile proteins whose level decreased to weak.

*Lot D (400 mg/L SDS)*

Toxic effects of SDS on the digestive gland were more severe than those observed at previous concentrations. Degeneration and dilation of digestive diverticula was notorious and even tubule breakdown was generalized.

Histochemical techniques could not be applied due to the severe destruction of the structure of the digestive gland.

**Discussion**

Studies performed until now about the effects of surfactants on survival and morpho-histochemical aspects in oysters are very limited.

The LC50 at 96 h for oyster *Crassostrea angulata*, Lmk. was found to be 136 mg/L SDS. It appeared to be much higher than that reported for *Carassius auratus* L. (Marchetti, 1964) and *Sparus aurata* L. (Ribelles et al., 1995a-c) that were 2.8 mg/L SDS and 6.1 mg/L SDS respectively. In agreement with Gilbert and Pettigrew (1984) it is a remarkable fact that molluscs are more resistant than fish to the deleterious effects of surfactants. The difference in tolerance among these species could be due in part to the different nature of the studied species (it may be noted that oysters are filtrating molluscs accustomed to withhold filtrated substances) and in part to the different place they occupy in the aquatic environment (gilthead due to its pelagic nature

**Table 3.** Histochemical reactions on carbohydrates and proteins in Epithelial ciliated cells of the digestive gland of *Crassostrea angulata*, Lmk. exposed to different concentrations of Sodium Dodecyl Sulphate (SDS).

REACTIONS	CT	A	B	C	D
PAS (McManus, 1948) Adjacent hydroxyl groups	2	1	1	1	NP
DIASTASE-PAS (Lillie and Greco, 1947) Glycogen	2	1	1	1	NP
ALPHA-AMILASE-PAS (Lillie and Greco, 1947) Neutral mucosubstances and/or glycoproteins, excepting glycogen	1	0	0	0	NP
ALCIAN – BLUE pH 2.5 (Martoja and Martoja-Pierson, 1970) Carboxyl-rich glycoconjugates, sulphated or not	0	0	0	0	NP
ALCIAN – BLUE pH 1 (Martoja and Martoja-Pierson, 1970)	0	0	0	0	NP
ALCIAN – BLUE pH 0.4 (Martoja and Martoja-Pierson, 1970) Sulphated glycoproteins, strongly ionized	1	0	0	0	NP
BROMOPHENOL BLUE-Hg (Chapman, 1971) Proteins in generals	0	0	0	0	NP
HARTIG ZACHARIAS (Martoja and Martoja-Pierson, 1970) Siderophile proteins	2	2	2	1	NP
POTASSIUM FERRICYANIDE- Fe (III) (Chevremont and Frederic, 1943) Proteins rich in SH groups	1	0	0	0	NP
THIOGLICOLATE POTASSIUM FERRICYANIDE -Fe (III) (Chevremont and Frederic, 1943) Proteins rich in S-S groups	1	1	1	1	NP

CT: control group; A: 50 mg/L SDS; B: 100 mg/L SDS; C: 200 mg/L SDS; D: 400 mg/L SDS. Results are expressed as semiquantitative assessment of color intensities by independent scores of three investigators. Estimated scale: 0, negative; 1, weak; 2, moderate; 3, strong; NP, has no been performed.

may be more influenced by surface agents than benthic oysters).

Based on the results of this study and according to Cairns and Scheier (1962), Ribelles et al. (1995a-c) and Rosety et al. (1997) the higher is the concentration of SDS, the less is the exposure time required for 50% mortality of the specimens.

In this experimental design, we have observed that exposure to anionic surfactant SDS caused several forms of histopathological and histochemical changes in the digestive gland of treated specimens, and these modifications were correlated to surfactant concentration. This relationship has also been reported by Ribelles et al. (1995a,b) and Rosety et al. (1997) in the liver, pancreas and gills and in kidney and spleen, respectively of Gilthead (*Sparus aurata*, L.), using SDS as anionic surfactant.

We have observed severe degenerative changes such as a loss of diverticule lights, vacuolization of epithelium and increase of basal membrane thickness of tubules and diverticules.

Comparison with the previous assessment performed by Benjumea et al. (1996), indicated that similar changes appeared in the digestive gland of mussels (*Mytilus galloprovincialis*, Lmk) after being exposed to the same anionic surfactant. These results were partially in concordance with those reported by Sarasquete et al. (1992) as effects of exposure to cadmium and copper in the digestive gland of mussels (*Mytilus galloprovincialis*, Lmk.) and clams (*Ruditapes philippinarum*). The above mentioned changes perturb the studied organ what may have influence on the survival of the treated oysters.

The histochemical distribution of carbohydrates and proteins of control oysters were similar to those obtained in the digestive gland of non-treated *Ostrea edulis* L. (Gonzalez de Canales et al., 1989).

The mode of action by which tensioactives produce their detrimental effects remains elusive (Helenius and Simmons, 1975). It's thought that the fall in surface tension induced by surfactants is the main cause of death (Prat and Giraud, 1964; Mann, 1972). However, it has also been claimed that surface tension has little to do with the toxic effects of surfactants on aquatic species (Muller, 1980; Marchetti, 1985). In agreement with Sprague (1976) and Mallat (1985) this work could not confirm a single cause of death. Rather, the decrease in surface tension, destruction of tissue, and repercussions at the organ levels may be co-contributors to the death of the oysters exposed to SDS.

## References

- Abel P. (1974). Toxicity of synthetic detergents to fish and aquatic invertebrates. *J.Fish. Biol.* 6, 279-298.
- Alzieu C. (1998). Tributyltin: Case study of a chronic contaminant in the coastal environment. *Ocean Coast. Manage.* 40, 23-36.
- Benjumea A., Carrasco C., Ribelles Garcia A. and Rosety Plaza M. (1996). Efectos toxicos causados por un detergente anionico (Dodecil Sulfato Sodico) sobre branquias de *Mytilus Galloprovincialis*, Lmk. IV Jornadas Salud y Medio Ambiente. Jorma IV. pp 168-172.
- Blasco J., Gonzalez-Mazo E. and Sarasquete C. (1999). Linear alkylbenzene sulphonates (LAS) and bioaccumulation of heavy metals (Cu and Pb) in *Ruditapes philippinarum*. *Toxicol. Environ.* 1, 1-10.
- Bogan R. (1955). Biodegradability of alkyl-sulphates. *Sewage Ind. Waste* 27, 217-228.
- Cairns J. and Scheier A. (1962). The acute and chronic effects of sodium alkylbenzene sulphate upon the pumpkinseed sunfish (*Lepomis gibbosus*, L.) and bluegill sunfish (*Lepomis macrochirus*, R.). *Proc. 17th Ind. Waste Conf. Prude Univ. Eng. Ext. Ser.* pp 14-28.
- Castelló Orvay F. (1993). Acuicultura marina. Fundamentos biológicos y tecnológicos. Publicaciones de la Universidad de Barcelona. pp 93-107.
- Chapman D.M. (1971). Dichromatism of bromophenol blue, with an improvement in the mercuric bromophenol blue technic for protein. *Stain Technol.* 50, 25-30.
- Chevremont M. and Frederic J. (1943). Une nouvelle methode de mise en evidence des substances e fraction sulphdryle. *Arch. Biol.* 54, 589-591.
- Dennis C. (1998). The Bras D 'Or Lakes oyster industry. *J. Shellfish Res.* 17, no. 4, (np).
- Fendinger N.J., Versteeg D.J., Weeg E., Dyer S. and Rapaport R.A. (1994). Environmental behaviour and fate of anionic surfactants. In: *Environmental chemistry of lakes and reservoirs*. Baker L.A. (ed). *Advances in chemistry Series No. 237*. American Chemical Society. pp. 528-557.
- Flores V., Galan M. and Sales D. (1979). Contaminación de las aguas de la Bahía de Cádiz (II). *Ensayos generales de calidad de las aguas*. *Ing. Quim.* 125, 105-109.
- Flores V., Galan M. and Sales D. (1980). Contaminación de las aguas de la Bahía de Cádiz (IV). *Ensayos de biodegradabilidad con dodecilsulfato sódico*. *Ing. Quim.* 131, 81-111.
- García Dominguez J.J. (1986). *Tensioactivos y detergencia*. Ed. Dossat. Madrid.
- Gardiner M.S. (1992). *Biología de los invertebrados*. Ed. Omega. pp 312-318.
- Gilbert P. and Petigrew R. (1984). Surfactans and the Eviroment. *Int. J. Cosmetic Sci.* 6, 149-158.
- Gonzalez de Canales M.L., Sarasquete M.C. and Gutierrez M. (1989). Histoquímica de carbohidratos y proteínas en la glándula digestiva y tejido conectivo de *Ostrea edulis* L. *Cuad. Invest. Biol.* 14, 11-22.
- Gutierrez M. (1967). Coloracion histologica para ovarios de peces, crustaceos y moluscos. *Investigaciones Pesqueras* 31, 265-271.
- Helenius A. and Simons K. (1975). Solubilization of membranes by detergents. *Biochem. Biophys. Acta* 415, 29-79.
- Lillie R.D. and Greco J. (1947). Malt diastase and ptyalin in place of saline in the identification of glycogen stain. *Stain Technol.* 22, 67-70.
- Loomis T.A. (1982). *Fundamentos de toxicología*. Ed. Acribia. Zaragoza. pp 29-44.
- Lopez-Artiguez M., Soria M.L. and Repetto M. (1989). Heavy metals in bivalve molluscs in the Huelva Estuary. *Bull. Environ. Contam. Toxicol.* 42, 634-642.
- Mallat J. (1985). Fish gill structural changes induced by toxicants and other irritants: A statistical review. *Can. J. Fish Aquat. Sci.* 42, 630-648, 1985.

*Effects of SDS on the digestive gland of the Portuguese oyster*

- Mann H.G. (1972). Toxicity and degradation of tensides in sea water. In: Marine pollution and sea life. FAO. Roma. pp 248-249.
- Marchetti R. (1964). Indagini sulla tossicità di alcuni tensioattivi nei riguardi dei pesci. Riv. Ital. Sost. Gras. XLI, 533-538.
- Marchetti R. (1985). Critical review of the effects of synthetic detergents on aquatic life. C.P.C.W. Studies and Review. FAO. Roma.
- Martoja R. and Martoja-Pierson M. (1970). Técnica de histología animal. Ed. Toray-Masson S.A. Barcelona. pp 176-208.
- Mayolle E. (1962). Les industries du savon et les détergents. Presses Universitaires de France. Paris.
- McManus J.F.A. (1948). Histological and histochemical uses of periodic acid. Stain Technol. 23, 99-108.
- Muller R. (1980). Fish toxicity and surface tension of non-ionic surfactants: investigations and antifoam agents. J. Fish. Biol. 16, 585-589.
- Norena-Barroso E., Gold-Bouchot G., Zapata-Perez O. and Sericano J.L. (1999). Polynuclear aromatic hydrocarbons in American oysters *Crassostrea virginica* from the Terminos Lagoon, Campeche, Mexico. Mar. Pollut. Bull. 38, 637-645.
- Prat R. and Giraud A. (1964). The pollution of water by detergents. OECD. Paris. Publication n° 16601.
- Ribelles A., Carrasco C. and Rosety M. (1995a). Morphological and histochemical changes caused by sodium dodecyl sulphate on the gills of gilthead, *Sparus Aurata* L. Eur. J. Histochem. 39, 141-148.
- Ribelles A., Carrasco C., Rosety M. and Aldana M. (1995b). Morphological and histochemical changes on the liver and pancreas of gilthead, *Sparus Auratus* L., induced by acute action of the anionic detergent, sodium dodecyl sulphate. Histol. Histopathol. 10, 781-787.
- Ribelles A., Carrasco C., Rosety M. and Aldana M. (1995c). A histochemical study of the biological effects of sodium dodecyl sulphate on the intestine of gilthead seabream, *Sparus Aurata* L. Ecotoxicol. Environ. Saf. 32, 131-138.
- Rosety M., Ribelles A. and Carrasco C. (1997). A morphological study in the kidney and spleen of gilthead, *Sparus aurata*, L. caused by sodium dodecyl sulphate. Histol. Histopathol. 12, 925-929.
- Sarasquete M.C., Gonzalez de Canales M.L. and Gimeno S. (1992). Comparative histopathological alterations in the digestive gland of marine bivalves exposed to Cu and Cd. Eur. J. Histochem. 36, 223-232.
- Sarasquete M.C., Gonzalez de Canales M.L., Blasco J., Capeta da Silva D., Arellano J.M. and Gutierrez M. (1997). Histochemical distribution and accumulation of trace metals in the heart of Green and Normal *Crassostrea angulata* specimens from different Southwest Spanish coasts. Eur. J. Histochem. 41, 139-148.
- Sprague J.B. (1976). The ABC's of pollutant bioassay using fish. In: Biological methods for the assesment of water quality. Cairn J. Jr. and Dickson K.L. (eds). American Society for testing and materials. Philadelphia. pp 6-30.
- Yoon H.D., Kim J.H., Lee H.J. and Kim S.J. (1996). Residues of organochlorine insecticides in sea water and shellfish in designated areas. Bull. Natl. Fish. Res. Dev. Agency (Korea), 52, 107-124

Accepted July 3, 2000